

Sudden and Unexplained Death in an Infant: Sickle Cell Crisis

DHIRAJ B NIKUMBH, SUNIL V JAGTAP, ROOPALI K MALI, GAURAV JAIN, WASIM KHATIB.

ABSTRACT

Sickle cell syndromes are remarkable for their clinical heterogeneity, including their presentations as sudden and unexpected deaths due to a sickle cell crisis. Such cases are accompanied by various provocative factors like exertions (exercise), dehydration, hypoxia, and infections. The sudden and unexpected death of an apparently healthy baby is a tragedy for its parents, grandparents and siblings and for the paediatrician.

At the same time, these deaths are challenges for the forensic and paediatric pathologists.

We present here, a rare case of sudden and unexpected death in a 3-month old infant with undiagnosed sickle disease, which was not preceded by any provoking factor. We are presenting this case to emphasize that sickle cell crisis is one of the causes of sudden, unexplained infant deaths and to highlight the role of autopsy in such cases.

Key Words: Sickle cell crisis, sudden and unexpected deaths, infants.

INTRODUCTION

Sickle cell disease is an autosomal recessive, genetically transmitted haemoglobinopathy which is responsible for a considerable amount of morbidity and mortality.[1] Inherited haemoglobin disorders are caused by structural abnormalities including the abnormal synthesis of chains and they represent the serious monogenic disorders in the world. The most commonly occurring structural defect in haemoglobin is sickle cell haemoglobinopathy, which is prevalent in the tropical and subtropical regions of the world.[2] It is one of the most common hereditary diseases which occurs worldwide and which may affect any organ or system of the human body. It is an irreversible and an untreatable health problem which is predominantly seen among various tribes in the world. With its present rate of spread, in another 25 to 40 years, over 150 lakh children will suffer and die of sickle cell disease, and over 300 lakh people will inherit the abnormal haemoglobin trait.[3] In India, the haemoglobin S (HbS) was first detected in the Vedeloid tribes in the Nilgiri hills of Tamil Nadu and it was later discovered in other tribes also.[4] Its incidence varies from 5 to 34 % and it is mainly restricted to the tribal population.[5]

We report here, a rare case of sudden and unexpected death in a 3- month old infant from the tribal areas in the Nandurbar district of Maharashtra.

CASE REPORT

A 3-month-old female infant was brought to the civil hospital with a history of loss of consciousness while sleeping in the crib. On examination by the casualty medical officer, the patient was reported brought dead to the hospital by the parents. There was no preceding significant history of any other complaints. A post mortem examination was carried out to know the exact cause of the death and to rule out sudden infant death syndrome (SIDS) as per the history which was narrated by the parents. We received the gross specimen of the lungs, heart, liver, kidney, spleen and the brain for histopathological examination. On gross examination, all the pieces of the viscera were found to be unremarkable, except a congestion in the spleen.

Light microscopical examination of each organ piece was carried out and all the organs showed sickle cell crisis. The spleen showed partial architectural effacement by the sickle cells. The red pulp and the sinusoidal space within the pericapsular areas were packed with irreversibly tactoid sickled cells [Table/Fig 1 and 2] The rest of the organs showed the same microscopical picture and they were packed with sickle cells, especially the liver and the brain [Table/ Fig 3 and 4].

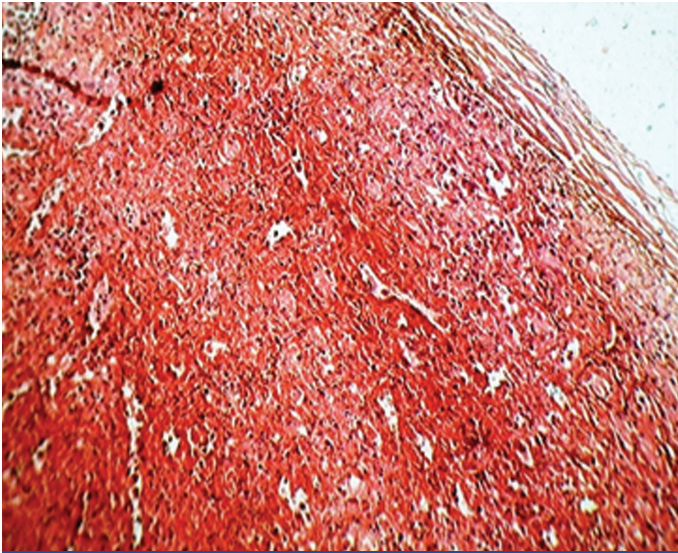
The final histopathological diagnosis was given as sickle cell crisis which led to an acute sequestration crisis and a vaso-occlusive crisis.

In view of the sudden and unexpected death of an infant, we did the peripheral smears, electrophoresis and the liquid chromatography (HPLC) of the parents. Both the parents were diagnosed as having a sickle cell trait (heterozygous disease).

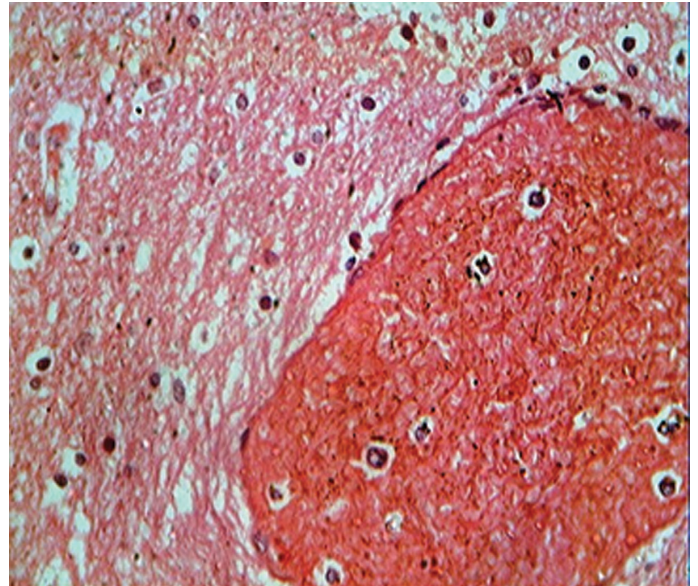
DISCUSSION

Sickle cell disease is a chronic condition with acute episodes which are related to vaso occlusion, leading to high mortality in the younger age group.[6] Virtually every system of the body can be affected by the ischaemia which results from the obstruction of the blood vessels by the clumps of the deformed erythrocytes. The strongest evidence implicates that intravascular sickling with tissue injury and even death is by an extreme exercise (exertion), with dehydration and relative hypoxia (altitudes).[7]

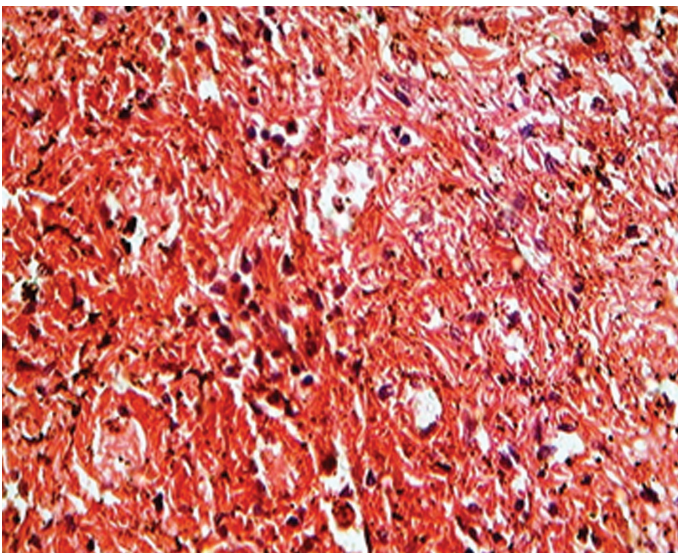
Ten percent of the total population of the state of Maharashtra belongs to the tribal population groups. A majority of them have a poor health status, peculiar health needs and a wide prevalence of red blood cell genetic disorders that complicate their health problems further.[8] There are three mountain ranges in the state of Maharashtra which are known as the Sahyadri, the Satpuda and the Gondwan ranges. Among the tribals in the Satpuda ranges -- Bhil, Pawara, Tadvi and Kortu are the major tribal groups. Our patient belonged to the Pawara tribal community.



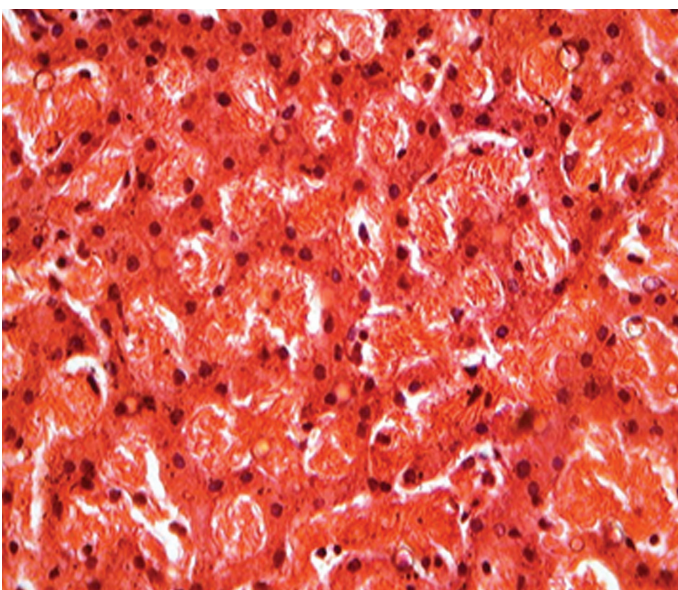
[Table/Fig-1]: Photomicrograph Of Spleen Showing Congested Appearance Due To Entrapped Sickle Cells In Parenchyma (H&E 10x).



[Table/Fig-4]: Photomicrograph Of Brain Showing Sickle Cells Packed In Cerebral Vessels. (H&E 40x).



[Table/Fig-2]: Photomicrograph Of Spleen Showing Red Pulp And Interstitium Packed And Filled With Irreversible Tactoid – Sickle Cells (H&E 40x).



[Table/Fig-3]: Photomicrograph Of Liver Showing Sickle Cells Packed In Sinusoidal Spaces (H&E 40x).

They remain backward, particularly in the health, education and the socio- economic aspects. The prevalence of sickle cell disorder in this tribal community is 20 – 25 %.[8]

Sickle cell disease is a hereditary blood disorder which is caused due to a defective haemoglobin structure. Haemoglobin is a tetramer which consists of two pairs of non- identical globin peptide chains, each chain being associated with one heme group. Sickle cell haemoglobin is a mutant form of normal adult haemoglobin, where glutamic acid is replaced by valine at the 6th globin chain. Under low oxygen concentrations, the mutant deoxyhaemoglobin polymerizes and eventually leads to a change in the red cell shape, giving a pointed tip to the RBCs, that means irreversible tactoid sickled RBCs.[8]

This phenomenon is called sickling and hence the mutant haemoglobin is called sickle cell haemoglobin (HbS).[8]

The most common cause of death for all the sickle cell variants and for all the age groups was infection (33- 44 %).[9] The terminal infection was heralded by upper respiratory tract syndromes in 72.6% and gastroenteritis in 13.7% of the infants. Other causes of death included stroke (9.8 %), splenic sequestration (6.6%), pulmonary emboli (4.9 %), renal failure (4.1 %), hepatic failure (0.8%) and left ventricular failure (0.4 %).[9]

The death was sudden and unexpected (40.8%) or it occurred within 24 hrs after the presentation (28.4%) and was usually associated with acute events (40.8%) as per Mancini EA et al.[9]

In our case, the 3-month-old infant presented with no significant complaints or history, except the loss of consciousness in the crib. The patient had no significant history in the past. Her parents belonged to the tribal/Pawara community, with a history of a consanguineous marriage. The histopathology revealed a sickle cell crisis in all the organs, especially in the spleen, liver, and the brain. To confirm the diagnosis, we did the HPLC of the parents, which showed that they were carriers of the sickle cell disorder. When two carriers marry, the chances of having a homozygous child is 25% in every pregnancy.[8] In our case, the patient may have suffered from homozygous disease, thus leading to the sudden and unexplained death in an undiagnosed sickle cell disease. Sickle cell crisis is a broad term for several acute conditions with sickle cell disease,

including acute sequestration crisis, vaso-occlusive crisis, and haemolytic crisis. Acute sequestration crisis is the most common disorder in young children which results from splenic enlargement due to a sudden accumulation of large quantities of blood. Further, it leads to severe anaemia, shock and death. This happened in our case.

Vaso- occlusive crisis results due to an aggregation of deformed erythrocytes i.e. clumps of sickled RBCs which obstruct the blood vessels. This results in ischaemia and infraction of the adjacent organs like the lung, liver, kidney, spleen and the cerebrum. During the periods of crisis, the susceptibility to infections in young children is increased mainly due to Pnemococcus and H.influenza. They lead to rapidly fatal systemic infections and severe septicaemia. [9,10]

Other causes of sudden death are pulmonary embolism, pulmonary haemorrhage, coronary arterial disease, infections, cerebral haemorrhage or infarction, etc.

Regarding the differential diagnosis – sudden infant death syndrome (SIDS)/crib death is still a leading cause of infant death and it occurs in infants who are found supine. The most common age group is 4 – 16 weeks old infants. The gross and the microscopical findings in SIDS remain constant, as in normal appearing infants with good nutritional states. Intrathoracic petechial haemorrhages have an emphasis on the thymic petechiae, heavy congested lungs, liquid blood, clenched hands, empty bladder and focal non-specific infection in the upper airways. SIDS may be traumatic or non-traumatic and it constitutes 57 % of the sudden deaths in infancy which present to the forensic community. Therefore, SIDS is essentially a diagnosis of exclusion when other possibilities of diagnosis, including metabolic disorders have been ruled out.[10]

The differential diagnosis between sudden unexpected death and SIDS can be challenging to the pathologists, forensic experts and the paediatricians.[10] A thorough autopsy, review of the clinical

history and death scene investigation were important to diagnose SIDS.

To conclude

We presented this case to emphasize that sickle cell crisis is one of the causes of sudden unexplained infant deaths and to highlight the role of autopsy in such cases. Another aspect is preventive programmes on a trial basis among the tribal risk population, which include a simple screening by a sickling test, and electrophoresis / HPLC. Community awareness and marriage counseling programs are also helpful in preventing sickle cell disease.

REFERENCES

- [1] Kamble M, Chaturvedi P. Epidemiology of sickle cell disease in a rural hospital of central India. *Indian Paediatric* 2000; 37: 391-6.
- [2] Balgir RS. Hematological profile of twenty five tribal compound cases of haemoglobinopathies and G6PD deficiency in rural Orissa. *Indian Journal of Medical Sciences*.2008; 62 (9) :362 -71.
- [3] Commisionarate of tribal development and Commisionarate of Health and Family Welfare. Govt of Gujarat; Sickle Cell Disease Control and Research Project Gujarat. Dec 2007.
- [4] Lehmann H, Cutbush M. Sickle cell trait in southern India. *British Medical Journal* 1952;1 : 404 – 5.
- [5] Italia Y. A sickle cell disease book for health workers and sickle cell disease control programs. Commisionarate of Health and Family welfare. Govt of Gujarat. 2006 ; 1-3.
- [6] Patel MM, Moli JP, Patel SM, Patel RD. Vasoocclusion by sickled RBCS in 5 autopsy cases of sudden death. *Indian Journal of Pathology and Microbiology*.2007; 50:914-6.
- [7] Mitchell B.L. Sickle cell trait and sudden death – Bringing it home. *Journal of the National Medical Association*. 2007; 99(3) : 300- 5.
- [8] Kate SL . Health problems of the tribal population groups from the state of Maharashtra. *Indian Journal of Medical Sciences*. 2001 ; 55(2) :99 -108.
- [9] Mancini EA, Culberson DE, Yang YM, Gardner TM, Povell R et al. Causes of death in Sickle cell disease: an autopsy study. *British J Haematology*. 2003 ; 123 (2) : 359- 65.
- [10] Gilbert-Barness E. Sudden and unexplained death in infants. In: Enid Gilbert- Barness(editor). *Potters pathology of the fetus, Infant and Child*. 2nd edi. Vol 1, Mosby Elsevier pub.2007;841-7.

AUTHOR(S):

1. Dr. Dhiraj B Nikumbh
2. Dr. Sunil V Jagtap
3. Dr. Roopali K Mali
4. Dr. Gaurav Jain
5. Dr. Wasim Khatib.

PARTICULARS OF CONTRIBUTORS:

1. Corresponding Author
2. MD, Department of Pathology
Krishna Institute of Medical Sciences,
Karad, District - Satara, Maharashtra, India - 415110.
3. MBBS, Department of Anatomy
Krishna Institute of Medical Sciences,
Karad, District - Satara, Maharashtra, India - 415110.
4. MBBS, Department of Pathology
Krishna Institute of Medical Sciences,
5. MBBS, Department of Pathology
Krishna Institute of Medical Sciences
Karad, District - Satara, Maharashtra, India - 415110.

NAME, ADDRESS, TELEPHONE, E-MAIL ID OF THE CORRESPONDING AUTHOR:

Dr. Dhiraj B Nikumbh MD
Assistant Professor, Department of Pathology
SBH, Govt Medical College , Dhule
Maharashtra, India .
Mobile : 9226894980
Email : drdhirajnikumbh@rediffmail.com

DECLARATION ON COMPETING INTERESTS:

No conflicting Interests.

Date of Submission: **Jul 25, 2011**
Date of per review: **Sep 10, 2011**
Date of acceptance: **Sep 13, 2011**
Date of Publishing: **Nov 30, 2011**